

New insights into the treatment of myositis

Stefanie Glaubitz, Rachel Zeng and Jens Schmidt 

Ther Adv Musculoskel Dis

2020, Vol. 12: 1–14

DOI: 10.1177/
1759720X19886494

© The Author(s), 2020.
Article reuse guidelines:
[sagepub.com/journals-
permissions](https://sagepub.com/journals-permissions)

Abstract:

The myositis syndromes include polymyositis, dermatomyositis (DM), necrotizing myopathy, inclusion body myositis (IBM), antisynthetase syndrome and overlap syndromes with myositis. These syndromes mostly occur in middle-aged patients, while juvenile DM occurs in children and adolescents. Patients mostly show a subacute weakness and myalgia in the upper and lower limbs, the diagnosis is based upon these clinical findings in combination with muscle biopsy results and specific serum autoantibodies. In recent years, research achieved a better understanding about the molecular mechanism underlying the myositis syndromes, as well as disease progress and extramuscular organ manifestations, such as interstitial lung disease and association with neoplasias. Treatment mainly consists of glucocorticosteroids and immunosuppressants. IBM is usually refractory to treatments. This review provides an overview of the current standards of treatment and new treatment options like monoclonal antibodies and new molecular therapies and their first results from clinical trials.

Keywords: myositis, polymyositis, dermatomyositis, inclusion body myositis, necrotizing myopathy, antisynthetase syndrome, overlap syndrome

Received: 4 July 2019; revised manuscript accepted: 10 October 2019.

Introduction

In recent years, the treatment of myositis experienced a further development and improvement. Whereas previously corticosteroids were the only option and some expert options to other immunosuppressive treatment existed, several large studies and longlasting experiences are available today.

The aim of this review is to outline the current standard treatment of myositis and to provide an overview of new treatment options and recent clinical trials. A PubMed search of all relevant case reports, clinical trials and reviews, focusing on publications of the last 3 years, was undertaken. But where no data were available for the last 3 years, we included earlier studies, too. We discuss a wide range of immunosuppressive and immunomodulatory treatments, including conventional and novel biologic therapies, placing new developments in context with our current standard treatment of myositis. Furthermore, it is of utmost importance for patients that the treatment is done in a close interdisciplinary manner between rheumatologists, dermatologists, neurologists, pulmonologists, pathologists, and physical therapists.

Treatment of DM, PM, and OM including ASS

Polymyositis (PM), dermatomyositis (DM), necrotizing myopathy (NM), antisynthetase syndrome (ASS), overlap myositis (OM) and inclusion body myositis (IBM) are reviewed here. It is a diverse group of inflammatory muscle disorders, commonly characterized by progressive muscle weakness, myopathic findings on electromyography, elevated creatine kinase (CK) level in serum, as well as inflammatory infiltrates in muscle biopsy. The current classification of myositis and the diagnostic pathway have recently been reviewed.¹ The disease progress, organ manifestations, association with neoplasia, histopathological findings, presence of autoantibodies, and pathomechanism differ largely between the subtypes² and it is this heterogeneity that creates a challenge in treatment.

Glucocorticosteroids and adrenocorticotrophic hormone gel

The standard first-line treatment of DM, PM and OM are glucocorticosteroids, usually administered orally at a dose of prednisolone 0.5–1.0 mg/kg per day, and an initial intravenous (i.v.) high-dose pulse

Correspondence to:

Jens Schmidt
Department of Neurology,
Muscle Immunobiology
Group, Neuromuscular
Center, University Medical
Center Göttingen, Robert-
Koch-Sr. 40, 37075
Göttingen, Germany
j.schmidt@gmx.org

Stefanie Glaubitz
Rachel Zeng
Department of Neurology,
Muscle Immunobiology
Group, Neuromuscular
Center, University
Medical Center Göttingen,
Göttingen, Germany

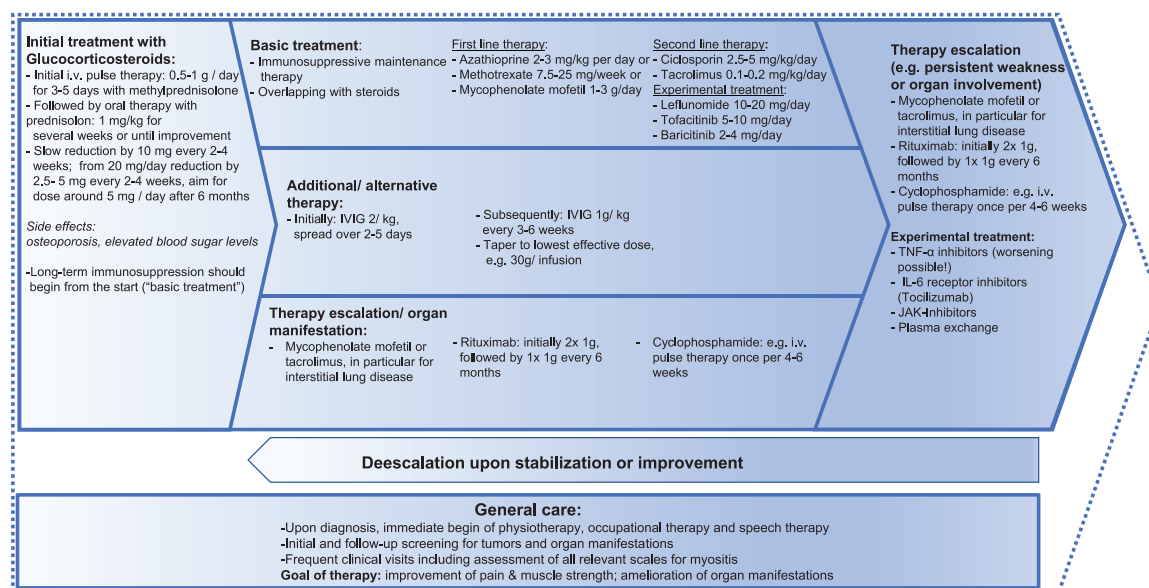


Figure 1. Overview of treatment essentials in PM, DM, NM, ASS and OM.

ASS, antisynthetase syndrome; DM, dermatomyositis; IL, interleukin; i.v.; intravenous; IVIg, intravenous immunoglobulin; JAK, Janus kinase; NM, necrotizing myopathy; OM, overlap myositis; PM, polymyositis; TNF α , tumor necrosis factor alpha.

with up to 1000mg methylprednisolone per day for 3–5 days, particularly in acute and severe cases (Figure 1). The potential side effects of corticosteroids are well known and include weight gain, osteoporosis, diabetes mellitus, hypertension, and increased risk for infections. These side effects can make treatment with corticosteroids, for certain patients, intolerable.

Adrenocorticotrophic hormone (ACTH) gel, also known as repository corticotropin injection (RCI), is a melanocortin peptide with mechanisms of action beyond steroidogenesis resulting in anti-inflammatory and immunomodulatory effects. The efficacy of RCI has been demonstrated in a number of retrospective case series.^{3,4} Recently, an open-label clinical trial tested RCI in patients with refractory adult PM and DM and showed clinical improvement in 7 out of 10 subjects. A significant reduction in concomitant steroid dosing after 24 weeks was noted with none of the patients developing weight gain or cushingoid features.⁵ Though it should be highlighted that three serious adverse events (SAEs) occurred during the trial, considered related to the study drug, including one with disseminated herpes zoster causing herpes pneumonitis. Therefore, more studies evaluating the efficacy and safety are necessary, before RCI may be considered a treatment option in patients with PM or DM, who do not respond to, or cannot tolerate, corticosteroids

and other immunosuppressants. RCI is approved by the US Food and Drug Administration for the treatment of myositis but has not yet been approved by the European Medicines Agency.

Immunosuppressants

An immunosuppressive maintenance therapy is usually started in parallel with corticosteroids, and the first immunosuppressive agents of choice include azathioprine (AZA), methotrexate (MTX), and mycophenolate mofetil (MMF; see Figure 1). A multicenter, randomized study also demonstrated a better efficacy of early combination therapy of MTX or ciclosporin with prednisone compared with prednisone alone in patients with new-onset juvenile DM, resulting in a shorter median time to clinical remission and prednisone discontinuation; while the side-effect profile favored the combination with MTX compared with ciclosporin.⁶

A recent study comparing the efficacy and adverse effects in 102 patients with ASS treated with AZA versus MTX showed similar effects in clinical outcome as well as similar prevalence of adverse events between the two immunosuppressants.⁷ The most common adverse effects included elevated liver enzymes and gastrointestinal involvement with slightly higher prevalence in patients treated with AZA, while two patients developed MTX-associated pneumonitis.

Several reports have shown a good response to MMF in patients with autoimmune- and myositis-associated interstitial lung disease, improving respiratory parameters such as forced vital capacity and diffusion capacity for carbon monoxide.^{8–10} A recent retrospective study evaluated the efficacy of AZA and MMF on myositis-associated interstitial lung disease in 110 patients, showing similar beneficial effect on lung function and steroid sparing with a lower prednisone dose required in patients treated with AZA after 36 months.¹¹ Notably, adverse events were more frequent with AZA than MMF treatment (33.3% *versus* 13.6%), with one patient being switched from AZA to MMF due to side effects. A better tolerability of MMF compared with AZA has also been described in the treatment of other inflammatory disorders such as systemic sclerosis.¹² MMF therefore presents an effective and mostly well-tolerated immunosuppressant for symptom control and sparing of corticosteroids.

The use of immunosuppressants increases risk for infections, especially in cases of severe leukopenia. Therefore, therapy with one of the immunosuppressants requires regular monitoring of relevant blood parameters including full blood count, liver, and renal function tests. Long-term use of AZA in particular shows a risk for certain malignancies such as lymphoma and non-melanoma skin cancer,¹³ therefore special measures such as sun protection and regular dermatological screenings are necessary. MTX bears a recognized risk for pulmonary toxicity,¹⁴ which presents a rare but severe side effect.

Calcineurin inhibitors

Cyclosporin A and tacrolimus are calcineurin inhibitors that exert their major therapeutic effects by inhibiting T-cell-mediated immune responses and thus suppressing the production of interleukin 2 (IL-2) and related cytokines. There is evidence for the positive effect of calcineurin inhibitors on muscular involvement in myositis, including a case series of eight patients [six had anti-Jo-1 and two had had antisignal recognition particle (anti-SRP) antibodies] with refractory myositis receiving treatment with tacrolimus,¹⁵ an observational study of 16 patients with PM and 15 patients with DM receiving treatment with tacrolimus¹⁶ and more recently, a multicenter, randomized study assessing ciclosporin with prednisone in patients with new-onset juvenile DM.⁶ Moreover, calcineurin inhibitors have been used in the treatment of myositis-associated interstitial lung disease (ILD)

since the 1990s, and recent case reports and retrospective studies support this by demonstrating better clinical outcome, successful tapering of corticosteroids, and improvement in pulmonary function tests and high-resolution computed tomography (HRCT).^{17–20} The beneficial effect was most evident if treatment was started during the early stage of the disease¹⁸ and the presence of antisynthetase antibodies seems to be related to a good response to calcineurin inhibitors.^{21,22}

Due to differences in the molecular way of inhibiting the activity of calcineurin and differences in pharmacodynamics, the pharmacological effect of tacrolimus is estimated to be 100 times stronger than that of ciclosporin A, and has a longer half-life than that of ciclosporin A.²³ This suggests that tacrolimus has some advantages over ciclosporin for the treatment of myositis and associated interstitial lung disease (ILD), but comparative studies are lacking.

Adverse events are generally similar between ciclosporin and tacrolimus and include hypertension, nephrotoxicity, hepatotoxicity, and malignancy. Therefore, monitoring of the serum levels of both drugs needs to be performed regularly. Additionally, both ciclosporin A and tacrolimus influence the cytochrome P 3A4, thus potential drug interactions need to be considered.

Calcineurin inhibitors can be considered as an alternative option in case of insufficient response to the standard therapy used in combination with other immunosuppressive drugs. The effectiveness of calcineurin inhibitors in the treatment of myositis-associated ILD is highly promising, yet randomized prospective multicenter studies in patients with myositis-associated-ILD are still needed.

Intravenous immunoglobulin (IVIg)

IVIg serves as an alternative option or add-on treatment in case corticosteroids and standard immunosuppressants are not tolerated or not sufficiently effective, (see Figure 1). Two randomized, double-blind, placebo-controlled studies have been performed to evaluate the efficacy of IVIg in the treatment of PM and DM, one including 15 patients with refractory DM, showing a clear benefit under treatment with IVIg compared with placebo,²⁴ and the other involving 26 patients with steroid-refractory PM and DM, the latter trial showing no significant difference in clinical improvement between the IVIg group and the

placebo group; the authors attribute this to selection bias and the small number of patients included.²⁵ Other sources that support the use of IVIg in inflammatory myopathies are open, uncontrolled prospective and retrospective studies as well as case series (recent overview in Anh-Tu Hoa and Hudson²⁶). Apart from the treatment of muscular symptoms, IVIg has also been reported to be effective in therapy refractory ILD and esophageal involvement related to PM and DM.^{27–29} A recent retrospective case review of 42 patients with refractory cutaneous DM treated with IVIg showed improvement of skin manifestations in 35 out of 42 patients (83%); 80% of the patients also had decrease of corticosteroids and immunosuppressive agents under IVIg treatment in the course of disease.³⁰ A double-blind, randomized, placebo-controlled, multicenter phase III study to evaluate the efficacy and safety of IVIg in patients with refractory DM ('ProDERM study') [ClinicalTrials.gov identifier: NCT02728752] has recently completed recruitment and data are awaited soon.

Especially in cases where corticosteroids or immunosuppressants are contraindicated, such as severe infections or neoplasia, IVIg serves as a reasonable option of treatment.

IVIg is usually applied at 1–2 g/kg every 3–6 weeks at a typical daily dose of about 0.5–1 g/kg. The individual dose, time interval between cycles and the number of treatment cycles needed to achieve stability need to be identified individually for each patient. A continuous close monitoring of the clinical response and disease activity is required.

Across all studies and case series so far, IVIg appears to be well tolerated and safe. Potential side effects include allergic reactions, thrombosis, hemolysis, and infusion reactions with headache, fever, and chills; many side effects are associated with the dose and the infusion rate.

Subcutaneous administering of immunoglobulins (SCIg) is associated with fewer systemic side effects and has become increasingly popular in recent years. Through the possibility of a home-based setting, SCIg has also contributed to the autonomy and quality of life of patients. There are case reports and cohort studies on patients with PM or DM, who were switched from IVIg to a maintenance therapy with SCIg, showing favorable clinical response and a good tolerability.^{31–34} The most common side effects were injection-site reactions,

especially if larger volumes need to be administered, which required frequent administering at multiple sites.

Cyclophosphamide

Cyclophosphamide (CYC) usually serves as treatment escalation when standard immunosuppression and IVIg are not sufficient in severe cases of myositis, especially with systemic organ involvement, including lung and cardiac disease. Several uncontrolled cohort studies have demonstrated the efficacy of CYC in the treatment of severe myositis and myositis-associated ILD, with the majority of patients improving in both muscular strength and pulmonary function.³⁵ A recent retrospective report also describes the use of oral CYC in a cohort of severe, refractory myositis, including nine patients with DM, three patients with PM, and two patients with NM.³⁶ All patients received concurrent medication with IVIg or rituximab, respectively, and glucocorticoid. The data showed a significant improvement in disease-activity measures and reduction in glucocorticoid dosing; the authors also hypothesize that the higher cumulative CYC dose with daily oral administration compared with IV pulse dosing provide more efficacy, without marked increase of side effects. The most common adverse events noted were respiratory infections followed by leukopenia. In a larger retrospective cohort study of 56 patients with juvenile DM treated with CYC and with a median follow-up duration of 7.8 years, there were only minor adverse events reported in three patients, mainly being respiratory infections.³⁷ However, the authors acknowledge that the available data are insufficient to fully evaluate long-term side effects such as malignancy and infertility, especially since adults normally receive higher doses of CYC.

Therefore, CYC is still reserved only for severe cases of myositis or systemic organ involvement such as the lung (ILD). Potentially severe adverse events include infections, myelosuppression, renal toxicity, infertility, and secondary malignancy. Combination therapy with other immunomodulatory drugs seem promising, as in the study mentioned above, as well as in another recent case report.³⁸

Rituximab

Rituximab is a chimeric monoclonal antibody against the CD20 antigen expressed on the surface of B lymphocytes leading to their depletion in the

peripheral blood. Several case reports, case series and open-label trials have suggested a beneficial effect of rituximab in patients with refractory myositis (recent overview in research by Fasano and colleagues³⁹). The largest randomized, double-blind, placebo-controlled trial so far regarding the efficacy of rituximab in adult and juvenile myositis is the rituximab in myositis (RIM) trial, which included 195 individuals (75 with PM, 72 with DM, and 48 with juvenile DM) refractory to glucocorticoids and at least one immunosuppressive agent.⁴⁰ Although the primary endpoint was not reached, the majority of patients (83%) showed a clinical improvement and a steroid-sparing effect during the trial. The rituximab treatment was generally well tolerated; the most common adverse events noted were infections. In a *post hoc* analysis of the RIM trial, the presence of anti-Jo1 and anti-Mi-2 antibodies seem to be predictors of a good response to rituximab;⁴¹ both antibody levels decreased after B-cell depletion and correlated with changes in disease activity.⁴² The efficacy of rituximab in ASS was further evaluated in a registry-based study of 43 patients, comparing the clinical response after several rituximab cycles in antisynthetase antibody-positive and -negative patients.⁴³ The study found a significant steroid-sparing effect only in the antibody-positive group, though both groups showed a clinical improvement regardless of their antibody status.

A recent retrospective cohort study of 43 patients with refractory myositis (15 ASS, 16 DM, 12 PM) also suggests efficacy of rituximab by demonstrating a clinical and laboratory improvement in 75% of the patients at 1 year, as well as a significant reduction/discontinuation of glucocorticoids.⁴⁴

The current evidence in literature therefore supports the off-label use of rituximab in patients with refractory myositis, although the role of B lymphocytes in the pathogenesis of myositis is not yet well understood. Common adverse events during treatment with rituximab such as infusion reactions, possible cardiotoxic effects and serious infections have to be considered.

Abatacept

Abatacept is a human fusion protein of cytotoxic T-lymphocyte protein 4 (CTLA4) and the fragment-crystallizable portion of IgG1 that blocks T-cell costimulation. A recently published randomized, open-label trial with delayed-start design suggests a beneficial response to abatacept

treatment in 20 patients with either refractory DM or PM.⁴⁵ The trial showed a significant improvement in muscle strength and health-related quality of life in half of the patients after treatment with i.v. abatacept for 6 months. The therapy was generally well tolerated. These positive results have led to an ongoing phase III, randomized, double-blind trial evaluating the efficacy and safety of abatacept in myositis [ClinicalTrials.gov identifier: NCT02971683]; its completion date is estimated for June 2021.

Anti-TNF α therapies

Tumor necrosis factor alpha (TNF α) inhibitors include monoclonal antibodies such as infliximab or circulating receptor fusion proteins such as etanercept. The current evidence in literature for anti-TNF α therapies in myositis are variable, with some reports and trials suggesting a beneficial effect in patients with myositis, while others report no efficacy or even worsening of symptoms after TNF α inhibitor treatment (recent overview by Oddis and Aggarwal⁴⁶). A recent randomized, double-blind, placebo-controlled trial evaluating the efficacy of infliximab in refractory PM and DM also showed no significant effect with only 4 out of 12 patients responding to treatment with infliximab.⁴⁷ Furthermore, there are reports that TNF α inhibitors might even induce myositis.⁴⁸ Therefore, the use of TNF α inhibitors in the treatment of myositis cannot be supported at present.

Tocilizumab

The use of tocilizumab, an interleukin 6 (IL-6)-receptor antagonist, has been reported only in a few case reports so far; the first report involving two patients with refractory Jo-1-positive PM, who showed a decrease of serum CK levels and resolution of inflammatory signs in muscle magnetic resonance imaging (MRI) after tocilizumab treatment;⁴⁹ in another report, a patient with an overlap syndrome involving DM and systemic sclerosis, refractory to multiple therapies, showed improvement in clinical and laboratory parameters after tocilizumab treatment.⁵⁰ A case involving a patient with anti-Jo1- and Ro52-antibodies positive ASS, who suffered from relapsing flares of myositis and arthritis with insufficient response to multiple therapies, also demonstrated clinical improvement and normalization of C-reactive protein and CK levels after additional treatment with tocilizumab.⁵¹ A randomized, double-blind,

controlled phase II trial evaluating the efficacy of tocilizumab in myositis patients is ongoing [ClinicalTrials.gov identifier: NCT02043548].

Anakinra

Anakinra, an IL-1 receptor antagonist, was tested in a small case study of 15 patients with refractory myositis.⁵² Seven patients had clinical response according to the core set measures of disease activity International Myositis Assessment and Clinical Studies (IMACS), four of them also showed improvement in functional index scores. The data still require confirmation by randomized, controlled studies.

Sifalimumab

Accumulating evidence in the literature supports an important role of interferon (IFN) α/β -mediated immunity in the pathogenesis of myositis, showing overexpression of IFN-induced genes and IFN-regulated cytokines in blood samples from DM and PM.^{53,54} Sifalimumab is an anti-IFN α monoclonal antibody and its effect was investigated in a phase Ib randomized, double-blind, controlled clinical trial in PM and DM.⁵⁵ Treatment with sifalimumab resulted in suppression of the IFN signature in blood and muscle tissue in myositis patients which correlated with clinical improvement. Subsequent trials are awaited.

JAK inhibitors

Janus kinases (JAKs) are a family of enzymes that play a crucial role in the interferon-mediated activation of cytokine receptors *via* phosphorylation, which, in turn, enables the recruitment of signal transducer and activator of transcription (STAT) factors that modulate gene expression. JAK inhibitors block the activity of JAKs, thus inhibiting the signaling of different IFNs and ILs. Accumulating evidence points to an important role of IFN-mediated responses and the JAK-STAT pathway in the pathogenesis of DM.^{53,56,57} The effectiveness of JAK inhibitors has already been shown in various inflammatory diseases (overview by Schwartz and colleagues⁵⁸). Ladislau and colleagues demonstrated the pathogenic role of IFN on muscular and endothelial cells *in vitro* and also reported on the treatment with ruxolitinib (a JAK 1/2 inhibitor) in four adult patients with refractory DM, who improved in muscle weakness and skin lesions, while

showing reduced serum levels of IFN.⁵⁹ The use of another JAK inhibitor tofacitinib (a JAK 1/3 inhibitor) has been shown in a few case reports, comprising nine adult patients with refractory DM in total, with the majority improving clinically.⁶⁰⁻⁶² Regarding treatment with JAK inhibitors in juvenile DM, two case reports have been published so far.^{63,64}

Recently, preliminary results of an open-label pilot study evaluating tofacitinib in nine adult patients with refractory DM were presented.⁶⁵ All nine patients showed minimal to moderate improvement after 12 weeks of treatment, with no reported serious adverse events.

Further randomized controlled trials are expected to evaluate the efficacy and safety of JAK inhibitors.

Plasma exchange in myositis

There are few data in the literature that demonstrate the effects of plasma exchange in myositis; some up to 30 years ago. In a retrospective study of 38 patients who had a plasma exchange between 1980 and 1986, 24 patients improved in functional status. The efficacy was even higher in acute disease progression. Of these 38 patients, 34 received the therapy after failure of a conventional therapy. In 4 cases, plasma exchange was the initial therapy.⁶⁶

Another multicenter study could only show improvement in severe acute forms of myositis.⁶⁷ A controlled trial compared plasma exchange with a sham apheresis and showed no significant improvement in muscle strength.⁶⁸

A current paper from 2015 reported three cases of myositis with severe pharyngo-esophageal muscle weakness, where plasma exchange was used successfully as a rescue therapy.⁶⁹

Plasma exchange is not a common therapy in myositis. But it may serve as a possible treatment in acute forms of myositis where the conventional therapy has failed or cannot be applied due to side effects.

Treatment of NM

The treatment of NM follows the same general therapeutic concepts as PM or DM, yet patients with NM often show poor response to this standard

regimen and may require an early treatment escalation or add-on therapy. A case series of three patients with statin-triggered autoimmune myopathy, who were not given corticosteroids because of diabetes, showed a good clinical response to a monotherapy with IVIg.⁷⁰ Several reports support the use of rituximab in NM, especially in SRP-antibody positive patients.^{71,72} One case report also describes the successful use of CD34+ autologous stem-cell transplantation in a patient with anti-SRP myositis, previously unresponsive to multiple immunosuppressants including IVIg, cyclophosphamide, alemtuzumab and infliximab.⁷³

Treatment of IBM

Patients with IBM are usually above the age of 50 years. The disease leads to a slowly progressive, asymmetrical weakness of the upper and lower limbs. The quadriceps muscle weakness leads to falls and difficulties in rising from a chair or climbing stairs. The finger flexion is also typically involved. An important clinical feature in around two thirds of IBM patients is dysphagia, which can even be the initial presenting symptom, and which may be so severe that it causes aspiration.

No effective treatment of IBM has been identified so far.⁷⁴ The standard regimen as used for other forms of myositis, as discussed above, does not stabilize IBM.⁷⁴ A double-blinded, placebo-controlled study with methotrexate showed no difference in progression and muscle strength over a timespan of 48 weeks.⁷⁵

The weakness is progressive and leads to a loss of function and an impairment in activities of daily living. After 10 years, the patients are mostly dependent on wheelchairs.⁷⁶ Dysphagia affects up to 70% of patients with IBM. It can lead to severe complications.⁷⁷ Botulinum toxin injections into the upper oesophageal sphincter can improve dysphagia.^{78–80}

Intravenous immunoglobulin (IVIg)

Studies with IVIg in IBM showed conflicting results. A long-term follow-up study examined the muscle strength and the patient subjective assessment in 16 patients with IBM. Three patients showed an improvement in swallowing, and a noticeable improvement in muscle strength was shown in two patients. However, the

short-term effects were not sustained over time.⁸¹ In placebo-controlled clinical trials, mild positive effects in muscle strength and swallowing were reported.^{82,83} All clinical trials missed their primary outcome. Therefore, IVIGs are not used by most experts. A major shortcoming of these trials is a duration of 3–6 months, which, according to current understanding, is too short for evaluating a chronic disease such as IBM. Cherin and colleagues published a case report about six IBM patients with subcutaneous IVIg therapy. All these patients showed an improvement in muscle strength and resolution in dysphagia. The duration of treatment rises from 4.5 months to 27 months.⁸⁴ Because of individual positive responses and to identify the patient collective which improves on IVIGs, a temporary probating treatment with IVIg can be tried, for example, 1–2 g/kg every 6–8 weeks for 6 months.⁷⁴

Infliximab

Infliximab was tested in 2008 in a cohort of four IBM patients and patients with different refractory myositis. In conclusion, no change in muscle strength was achieved and the therapy led to side effects, leading to a dropout of one of the patients. Moreover, the post-treatment MRI showed an increase of inflammation by 23%.⁸⁵

Etanercept

Etanercept, a tumor necrosis factor blocking agent, was tested in a small study with nine IBM patients. The patients received 25 mg etanercept twice a week and the outcome was defined in quantitative strength testing. Only small improvements in handgrip after 12 months of treatment could be found.⁸⁶

Anakinra

Anakinra was tested in several studies in patients with IBM. Anakinra is an IL-1-receptor antagonist and was tested with the aim of reducing amyloid by blocking IL-1 β and improve the muscle strength and function in daily living. A pilot study in 2013 showed no improvements.⁸⁷ In 2014, another study of 15 patients with refractory myositis was performed. Five of them suffered from IBM. The patients received an injection of anakinra daily for 12 months. One IBM patient showed improvements after 3 months, one worsened, and three showed no difference.⁵²

Lithium

In preclinical studies, lithium was highly promising as a treatment for IBM. Studies showed a reduction of amyloid- β precursor protein by lithium treatment.⁸⁸ Another trial used lithium for 1 year in 15 IBM patients. Nine of them completed the study and showed no improvement in muscle strength.⁸⁹ In view of the interesting approach of lithium treatment to reduce the degenerative proteins, more studies are required to explore the effects.

Rapamycin

Rapamycin is well known in preventing rejections after organ transplant and augmenting autophagic protein degradation. Recently, treatment with rapamycin in IBM was tested in a monocentric, randomized, double-blind, placebo-controlled phase II trial [ClinicalTrials.gov identifier: NCT02481453]. Over a period of 12 months, 22 patients received oral rapamycin and 22 participants received placebo. The quadriceps strength was used as the primary outcome and was not increased. However, the fatty-tissue replacement was reduced on MRI and the 6 min walking distance was improved after rapamycin versus controls.⁹⁰ A large, international trial is now awaited.

Follistatin

Follistatin gene therapy shows improvements in patients with Becker muscular dystrophy. Follistatin is a protein that blocks myostatin. The protein myostatin limits muscle growth and stops the muscles from hypertrophy. Therefore, follistatin gene therapy leads to muscle growth. A study published in 2017 evaluated follistatin gene therapy in IBM. In this trial, follistatin (rAAV1.CMV.huFS344) was injected in the quadriceps muscle of both sides in six patients. Patients received an exercise regime. The primary outcome was the distance the patients traveled in a 6 min walk test. Compared with untreated IBM patients matched for baseline measurements, age and sex, the Follistatin group showed an improvement of +56.0m/year. The untreated patients showed a decline of -25.8m/year in the 6min walk. Muscular biopsies showed a decrease in fibrosis.⁹¹ More research is required before follistatin could be recommended in IBM.

Arimoclomol

Arimoclomol leads to an increased production of heat-shock proteins. Heat-shock proteins are

normally produced as a reaction to cellular stress and might counteract and reduce the toxicity of cellular stress.⁹² Currently, arimoclomol is being tested in IBM in a phase II trial [ClinicalTrials.gov identifier: NCT02753530]. The study will continue for more than another year. The participants receive arimoclomol three times a day. The primary outcome measure is the decline of the IBM functional rating scale upon arimoclomol compared with placebo.

Alemtuzumab

Alemtuzumab binds to CD52, a glycoprotein that is expressed on mature T cells and B cells. A pilot trial with 13 patients with one series of alemtuzumab infusion over 4 days was performed. In some patients, the muscle strength improved. In general, the infusion could slow down the progression for up to 6 months and reduce the endomysial inflammation and stressor molecules in muscle biopsy.⁹³

Bimagrumab

Muscle mass is regulated by the myostatin/activating type II receptor pathway. The use of anti-ActRII antibodies leads to muscle hypertrophy in mouse models. The human anti-ActRII antibody is called bimagrumab.⁹⁴ Bimagrumab was tested in 14 patients with IBM. The patients treated with bimagrumab showed an increase in muscle mass and body volume. They showed an improvement in the 6 min walking distance compared with the placebo group.⁹⁵ In a recent double-blinded, multicenter trial, the primary endpoints (improving of muscle strength and the 6 min walking distance) could not be reached. However, the drug was well tolerated.⁹⁶

To assess the improvement by a certain treatment, it is important to consider that strength and function do not change linearly in IBM; rather, phases of stability and decline may follow each other.⁹⁷ To some extent, the heterogeneity might be explained by a different cytosolic 5'-nucleotidase 1A (anti-CN-1A) autoantibody status. Some 61% of patients with IBM have a positive anti-CN-1A-antibody status.⁹⁸ Anti-anti-CN-1A occurs in other diseases like Sjögren syndrome or systemic lupus erythematosus, too.⁹⁹

A study which compares IBM patients with and without a positive antibody status showed differences in histopathological, serological, and clinical

features. Compared with antibody-negative patients, IBM patients with a positive antibody status have a higher mortality risk, especially due to respiratory diseases and more facial weakness. During onset of the disease, patients with a negative status have more weakness of the proximal upper limbs.¹⁰⁰ Another study found that patients with a positive antibody status show more dysphagia and a reduced forced vital capacity. Additionally, they needed significantly more assistive devices like a wheelchair.¹⁰¹ Research in pathomechanism suggests that protein degradation in myofibers is affected by the anti-cN-1A autoantibodies.¹⁰²

In conclusion, many drugs have been tested for IBM. So far, no breakthrough has been achieved, but the number of ongoing and planned studies gives hope that we may see some light at the end of the tunnel.

Non-pharmacological treatment

Physical training in DM and PM leads to a stabilization of disease progression. In some studies with small groups of patients, an exercise program at home improved muscle strength and endurance.¹⁰³ In particular, concentric sport activities cause less injury to muscle fibers than eccentric sport activities. The stretching during eccentric sport activities can cause myalgia, elevated inflammatory activities, and an increase of CK. An immobilization in patients with myositis is obsolete.¹⁰⁴ Patients with IBM also show an improvement upon physical training: an aerobic training, which included cycling and resistance exercise over 12 weeks, three times per week, showed an improvement in muscle strength and was well tolerated. The CK levels did not change significantly after the training period.¹⁰⁵ A randomized single-blinded phase II trial tested a 12-week aerobic training program in patients with Charcot-Marie-Tooth disease type 1A (CMT) and IBM. The primary outcome was the peak oxygen uptake during a maximal exercise test. The results show that aerobic training clearly improves the primary outcome, especially in IBM. Another important aspect is the safety and feasibility of aerobic programs.¹⁰⁶ The evidence in the literature clearly supports moderate physical exercise in patients with myositis.

Conclusion

Currently, numerous immunosuppressive and immunomodulatory therapeutic agents are

available for the treatment of myositis. Glucocorticosteroids and immunosuppressants remain first-line therapy in DM, PM, NM, and OM, including ASS; early start and sufficient dosing can lead to stabilization of the disease, improvement of strength and decrease in inflammation. However, side effects of immunosuppressive treatment should not be underestimated. The refractory cases and extramuscular manifestations such as IDL, cardiac involvement, etc. should prompt early add-on or escalating treatments. Treatment of IBM remains a challenge. Novel therapeutic approaches targeting specific immunological pathways are highly promising. In order to evaluate their efficacy, large, randomized, controlled clinical trials are needed. Additionally, further research on the pathogenesis of myositis is essential to understand the different phenotypes and to better predict the response to a specific treatment. These efforts taken together may hopefully improve the treatment of myositis in the future.

Acknowledgements

Stefanie Glaubitz and Rachel Zeng contributed equally to this work. The authors are members of the European Reference Network for Rare Neuromuscular Diseases (ERN EURO-NMD).

Funding

The authors received no financial support for the research, authorship, and/or publication of this article.

Conflict of interest statement

JS has received personal fees, grants, or other support from Alnylam, Bayer, Biogen, BioMarin, Biotest, CSL Behring, Grifols, Kezar, LFB, Novartis, Octapharma, and Pfizer.

SG and RZ declare no conflict of interest.

ORCID iD

Jens Schmidt  <https://orcid.org/0000-0002-5589-2371>

References

1. Schmidt J. Current classification and management of inflammatory myopathies. *J Neuromuscul Dis* 2018; 5: 109–129.
2. Milone M. Diagnosis and management of immune-mediated myopathies. *Mayo Clin Proc* 2017; 92: 826–837.

3. Levine T. Treating refractory dermatomyositis or polymyositis with adrenocorticotropic hormone gel: a retrospective case series. *Drug Des Devel Ther* 2012; 6: 133–139.
4. Patel A, Seely G and Aggarwal R. Repository corticotropin injection for treatment of idiopathic inflammatory myopathies. *Case Rep Rheumatol* 2016; 2016: 9068061.
5. Aggarwal R, Marder G, Koontz DC, *et al.* Efficacy and safety of adrenocorticotropic hormone gel in refractory dermatomyositis and polymyositis. *Ann Rheum Dis* 2018; 77: 720–727.
6. Ruperto N, Pistorio A, Oliveira S, *et al.* Prednisone versus prednisone plus ciclosporin versus prednisone plus methotrexate in new-onset juvenile dermatomyositis: a randomised trial. *Lancet* 2016; 387: 671–678.
7. Casal-Dominguez M, Pinal-Fernandez I, Huapaya J, *et al.* Efficacy and adverse effects of methotrexate compared with azathioprine in the antisynthetase syndrome. *Clin Exp Rheumatol* 2019; 37: 858–861.
8. Morganroth PA, Kreider ME and Werth VP. Mycophenolate mofetil for interstitial lung disease in dermatomyositis. *Arthritis Care Res (Hoboken)* 2010; 62: 1496–1501.
9. Fischer A, Brown KK, Du Bois RM, *et al.* Mycophenolate mofetil improves lung function in connective tissue disease-associated interstitial lung disease. *J Rheumatol* 2013; 40: 640–646.
10. Tsuchiya H, Tsuno H, Inoue M, *et al.* Mycophenolate mofetil therapy for rapidly progressive interstitial lung disease in a patient with clinically amyopathic dermatomyositis. *Mod Rheumatol* 2014; 24: 694–696.
11. Huapaya JA, Silhan L, Pinal-Fernandez I, *et al.* Long-term treatment with azathioprine and mycophenolate mofetil for myositis-related interstitial lung disease. *Chest* 2019; 156: 896–906.
12. Owen C, Ngian GS, Elford K, *et al.* Mycophenolate mofetil is an effective and safe option for the management of systemic sclerosis-associated interstitial lung disease: results from the Australian Scleroderma Cohort Study. *Clin Exp Rheumatol* 2016; 34(Suppl. 100): 170–176.
13. McGurgan IJ and McGuigan C. Nonmelanoma skin cancer risk awareness in azathioprine-treated myasthenia gravis patients. *Brain Behav* 2015; 5: e00396.
14. Imokawa S, Colby TV, Leslie KO, *et al.* Methotrexate pneumonitis: review of the literature and histopathological findings in nine patients. *Eur Respir J* 2000; 15: 373–381.
15. Oddis CV, Sciruba FC, Elmagd KA, *et al.* Tacrolimus in refractory polymyositis with interstitial lung disease. *Lancet* 1999; 353: 1762–1763.
16. Mitsui T, Kuroda Y, Ueno S, *et al.* The effects of FK506 on refractory inflammatory myopathies. *Acta Neurol Belg* 2011; 111: 188–194.
17. Kotani T, Takeuchi T, Makino S, *et al.* Combination with corticosteroids and cyclosporin-A improves pulmonary function test results and chest HRCT findings in dermatomyositis patients with acute/subacute interstitial pneumonia. *Clin Rheumatol* 2011; 30: 1021–1028.
18. Go DJ, Park JK, Kang EH, *et al.* Survival benefit associated with early cyclosporine treatment for dermatomyositis-associated interstitial lung disease. *Rheumatol Int* 2016; 36: 125–131.
19. Witt LJ, Demchuk C, Curran JJ, *et al.* Benefit of adjunctive tacrolimus in connective tissue disease-interstitial lung disease. *Pulm Pharmacol Ther* 2016; 36: 46–52.
20. Sharma N, Putman MS, Vij R, *et al.* Myositis-associated interstitial lung disease: predictors of failure of conventional treatment and response to tacrolimus in a US cohort. *J Rheumatol* 2017; 44: 1612–1618.
21. Cavagna L, Caporali R, Abdi-Ali L, *et al.* Cyclosporine in anti-Jo1-positive patients with corticosteroid-refractory interstitial lung disease. *J Rheumatol* 2013; 40: 484–492.
22. Labirua-Iturburu A, Selva-O’Callaghan A, Martinez-Gomez X, *et al.* Calcineurin inhibitors in a cohort of patients with antisynthetase-associated interstitial lung disease. *Clin Exp Rheumatol* 2013; 31: 436–439.
23. Dumont FJ. FK506, an immunosuppressant targeting calcineurin function. *Curr Med Chem* 2000; 7: 731–748.
24. Dalakas MC, Illa I, Dambrosia JM, *et al.* A controlled trial of high-dose intravenous immune globulin infusions as treatment for dermatomyositis. *N Engl J Med* 1993; 329: 1993–2000.
25. Miyasaka N, Hara M, Koike T, *et al.* Effects of intravenous immunoglobulin therapy in Japanese patients with polymyositis and dermatomyositis resistant to corticosteroids: a randomized double-blind placebo-controlled trial. *Mod Rheumatol* 2012; 22: 382–393.

26. Anh-Tu Hoa S and Hudson M. Critical review of the role of intravenous immunoglobulins in idiopathic inflammatory myopathies. *Semin Arthritis Rheum* 2017; 46: 488–508.
27. Suzuki Y, Hayakawa H, Miwa S, *et al.* Intravenous immunoglobulin therapy for refractory interstitial lung disease associated with polymyositis/dermatomyositis. *Lung* 2009; 187: 201–206.
28. Marie I, Menard JF, Hatron PY, *et al.* Intravenous immunoglobulins for steroid-refractory esophageal involvement related to polymyositis and dermatomyositis: a series of 73 patients. *Arthritis Care Res (Hoboken)* 2010; 62: 1748–1755.
29. Bakewell CJ and Raghu G. Polymyositis associated with severe interstitial lung disease: remission after three doses of IV immunoglobulin. *Chest* 2011; 139: 441–443.
30. Galimberti F, Kooistra L, Li Y, *et al.* Intravenous immunoglobulin is an effective treatment for refractory cutaneous dermatomyositis. *Clin Exp Dermatol* 2018; 43: 906–912.
31. Danieli MG, Pettinari L, Moretti R, *et al.* Subcutaneous immunoglobulin in polymyositis and dermatomyositis: a novel application. *Autoimmun Rev* 2011; 10: 144–149.
32. Danieli MG, Moretti R, Gambini S, *et al.* Open-label study on treatment with 20% subcutaneous IgG administration in polymyositis and dermatomyositis. *Clin Rheumatol* 2014; 33: 531–536.
33. Patrick C, Jean-Christophe D, Jean-Charles C, *et al.* High-dose subcutaneous immunoglobulins for the treatment of severe treatment-resistant polymyositis. *Case Rep Rheumatol* 2014; 2014: 458231.
34. Hachulla E, Benveniste O, Hamidou M, *et al.* High dose subcutaneous immunoglobulin for idiopathic inflammatory myopathies and dysimmune peripheral chronic neuropathies treatment: observational study of quality of life and tolerance. *Int J Neurosci* 2017; 127: 516–523.
35. Ge Y, Peng Q, Zhang S, *et al.* Cyclophosphamide treatment for idiopathic inflammatory myopathies and related interstitial lung disease: a systematic review. *Clin Rheumatol* 2015; 34: 99–105.
36. Bae S and Charles-Schoeman C. Oral cyclophosphamide in treatment of patients with refractory idiopathic inflammatory myopathies: a retrospective observational study. *Clin Rheumatol* 2018; 37: 2113–2123.
37. Deakin CT, Campanilho-Marques R, Simou S, *et al.* Efficacy and safety of cyclophosphamide treatment in severe juvenile dermatomyositis shown by marginal structural modeling. *Arthritis Rheumatol* 2018; 70: 785–793.
38. Hisanaga J, Kotani T, Fujiki Y, *et al.* Successful multi-target therapy including rituximab and mycophenolate mofetil in anti-melanoma differentiation-associated gene 5 antibody-positive rapidly progressive interstitial lung disease with clinically amyopathic dermatomyositis. *Int J Rheum Dis* 2017; 20: 2182–2185.
39. Fasano S, Gordon P, Hajji R, *et al.* Rituximab in the treatment of inflammatory myopathies: a review. *Rheumatology (Oxford)* 2017; 56: 26–36.
40. Oddis CV, Reed AM, Aggarwal R, *et al.* Rituximab in the treatment of refractory adult and juvenile dermatomyositis and adult polymyositis: a randomized, placebo-phase trial. *Arthritis Rheum* 2013; 65: 314–324.
41. Aggarwal R, Bandos A, Reed AM, *et al.* Predictors of clinical improvement in rituximab-treated refractory adult and juvenile dermatomyositis and adult polymyositis. *Arthritis Rheumatol* 2014; 66: 740–749.
42. Aggarwal R, Oddis CV, Goudeau D, *et al.* Autoantibody levels in myositis patients correlate with clinical response during B cell depletion with rituximab. *Rheumatology (Oxford)* 2016; 55: 991–999.
43. Leclair V, Galindo-Feria AS, Dastmalchi M, *et al.* Efficacy and safety of rituximab in anti-synthetase antibody positive and negative subjects with idiopathic inflammatory myopathy: a registry-based study. *Rheumatology (Oxford)* 2019; 58: 1214–1220.
44. De Souza FHC, Miozzi R, de Moraes JCB, *et al.* Favorable rituximab response in patients with refractory idiopathic inflammatory myopathies. *Adv Rheumatol* 2018; 58: 31.
45. Tjarnlund A, Tang Q, Wick C, *et al.* Abatacept in the treatment of adult dermatomyositis and polymyositis: a randomised, phase IIb treatment delayed-start trial. *Ann Rheum Dis* 2018; 77: 55–62.
46. Oddis CV and Aggarwal R. Treatment in myositis. *Nat Rev Rheumatol* 2018; 14: 619.
47. Schiffenbauer A, Garg M, Castro C, *et al.* A randomized, double-blind, placebo-controlled trial of infliximab in refractory polymyositis and dermatomyositis. *Semin Arthritis Rheum* 2018; 47: 858–864.
48. Ishikawa Y, Yukawa N, Ohmura K, *et al.* Etanercept-induced anti-Jo-1-antibody-positive polymyositis in a patient with rheumatoid

- arthritis: a case report and review of the literature. *Clin Rheumatol* 2010; 29: 563–566.
49. Narazaki M, Hagihara K, Shima Y, *et al.* Therapeutic effect of tocilizumab on two patients with polymyositis. *Rheumatology (Oxford)* 2011; 50: 1344–1346.
 50. Kondo M, Murakawa Y, Matsumura T, *et al.* A case of overlap syndrome successfully treated with tocilizumab: a hopeful treatment strategy for refractory dermatomyositis? *Rheumatology (Oxford)* 2014; 53: 1907–1908.
 51. Murphy SM, Lilleker JB, Helliwell P, *et al.* The successful use of tocilizumab as third-line biologic therapy in a case of refractory anti-synthetase syndrome. *Rheumatology (Oxford)* 2016; 55: 2277–2278.
 52. Zong M, Dorph C, Dastmalchi M, *et al.* Anakinra treatment in patients with refractory inflammatory myopathies and possible predictive response biomarkers: a mechanistic study with 12 months follow-up. *Ann Rheum Dis* 2014; 73: 913–920.
 53. Greenberg SA, Pinkus JL, Pinkus GS, *et al.* Interferon-alpha/beta-mediated innate immune mechanisms in dermatomyositis. *Ann Neurol* 2005; 57: 664–678.
 54. Walsh RJ, Kong SW, Yao Y, *et al.* Type I interferon-inducible gene expression in blood is present and reflects disease activity in dermatomyositis and polymyositis. *Arthritis Rheum* 2007; 56: 3784–3792.
 55. Higgs BW, Zhu W, Morehouse C, *et al.* A phase 1b clinical trial evaluating sifalimumab, an anti-IFN-alpha monoclonal antibody, shows target neutralisation of a type I IFN signature in blood of dermatomyositis and polymyositis patients. *Ann Rheum Dis* 2014; 73: 256–262.
 56. Liao AP, Salajegheh M, Nazareno R, *et al.* Interferon beta is associated with type 1 interferon-inducible gene expression in dermatomyositis. *Ann Rheum Dis* 2011; 70: 831–836.
 57. Suarez-Calvet X, Gallardo E, Nogales-Gadea G, *et al.* Altered RIG-I/DDX58-mediated innate immunity in dermatomyositis. *J Pathol* 2014; 233: 258–268.
 58. Schwartz DM, Kanno Y, Villarino A, *et al.* JAK inhibition as a therapeutic strategy for immune and inflammatory diseases. *Nat Rev Drug Discov* 2017; 16: 843–862.
 59. Ladislau L, Suarez-Calvet X, Toquet S, *et al.* JAK inhibitor improves type I interferon induced damage: proof of concept in dermatomyositis. *Brain* 2018; 141: 1609–1621.
 60. Kurtzman DJ, Wright NA, Lin J, *et al.* Tofacitinib citrate for refractory cutaneous dermatomyositis: an alternative treatment. *JAMA Dermatol* 2016; 152: 944–945.
 61. Paik JJ and Christopher-Stine L. A case of refractory dermatomyositis responsive to tofacitinib. *Semin Arthritis Rheum* 2017; 46: e19.
 62. Kurasawa K, Arai S, Namiki Y, *et al.* Tofacitinib for refractory interstitial lung diseases in anti-melanoma differentiation-associated 5 gene antibody-positive dermatomyositis. *Rheumatology (Oxford)* 2018; 57: 2114–2119.
 63. Aeschlimann FA, Fremond ML, Duffy D, *et al.* A child with severe juvenile dermatomyositis treated with ruxolitinib. *Brain* 2018; 141: e80.
 64. Papadopoulou C, Hong Y, Omoyinmi E, *et al.* Janus kinase 1/2 inhibition with baricitinib in the treatment of juvenile dermatomyositis. *Brain* 2019; 142: e8.
 65. Paik J, Albayda J, Tiniakou E, *et al.* Study of tofacitinib in refractory dermatomyositis (STIR): an open label pilot study in refractory dermatomyositis [abstract]. *Arthritis Rheumatol* 2018; 70(Suppl. 10): abstract.
 66. Herson S, Lok C, Roujeau JC, *et al.* Plasma exchange in dermatomyositis and polymyositis. Retrospective study of 38 cases of plasma exchange. *Ann Med Interne (Paris)* 1989; 140: 453–455.
 67. Cherin P, Auperin I, Bussel A, *et al.* Plasma exchange in polymyositis and dermatomyositis: a multicenter study of 57 cases. *Clin Exp Rheumatol* 1995; 13: 270–271.
 68. Miller FW, Leitman SF, Cronin ME, *et al.* Controlled trial of plasma exchange and leukapheresis in polymyositis and dermatomyositis. *N Engl J Med* 1992; 326: 1380–1384.
 69. Cozzi F, Marson P, Pigatto E, *et al.* Plasma-exchange as a “rescue therapy” for dermatomyositis in acute phase. Experience in three young patients. *Transfus Apher Sci* 2015; 53: 368–372.
 70. Mammen AL and Tiniakou E. Intravenous immune globulin for statin-triggered autoimmune myopathy. *N Engl J Med* 2015; 373: 1680–1682.
 71. Valiyil R, Casciola-Rosen L, Hong G, *et al.* Rituximab therapy for myopathy associated with anti-signal recognition particle antibodies: a case series. *Arthritis Care Res (Hoboken)* 2010; 62: 1328–1334.

72. Pinal-Fernandez I, Parks C, Werner JL, *et al.* Longitudinal course of disease in a large cohort of myositis patients with autoantibodies recognizing the signal recognition particle. *Arthritis Care Res (Hoboken)* 2017; 69: 263–270.
73. Henes JC, Heinzelmann F, Wacker A, *et al.* Antisignal recognition particle-positive polymyositis successfully treated with myeloablative autologous stem cell transplantation. *Ann Rheum Dis* 2009; 68: 447–448.
74. Schmidt K and Schmidt J. Inclusion body myositis: advancements in diagnosis, pathomechanisms, and treatment. *Curr Opin Rheumatol* 2017; 29: 632–638.
75. Badrising UA, Maat-Schieman ML, Ferrari MD, *et al.* Comparison of weakness progression in inclusion body myositis during treatment with methotrexate or placebo. *Ann Neurol* 2002; 51: 369–372.
76. Benveniste O, Guiguet M, Freebody J, *et al.* Long-term observational study of sporadic inclusion body myositis. *Brain* 2011; 134: 3176–3184.
77. Lotz BP, Engel AG, Nishino H, *et al.* Inclusion body myositis. Observations in 40 patients. *Brain* 1989; 112: 727–747.
78. Liu LW, Tarnopolsky M and Armstrong D. Injection of botulinum toxin A to the upper esophageal sphincter for oropharyngeal dysphagia in two patients with inclusion body myositis. *Can J Gastroenterol* 2004; 18: 397–399.
79. Schrey A, Airas L, Jokela M, *et al.* Botulinum toxin alleviates dysphagia of patients with inclusion body myositis. *J Neurol Sci* 2017; 380: 142–147.
80. Di Pede C, Masiero S, Bonsangue V, *et al.* Botulinum toxin and rehabilitation treatment in inclusion body myositis for severe oropharyngeal dysphagia. *Neurol Sci* 2016; 37: 1743–1745.
81. Dobloug C, Walle-Hansen R, Gran JT, *et al.* Long-term follow-up of sporadic inclusion body myositis treated with intravenous immunoglobulin: a retrospective study of 16 patients. *Clin Exp Rheumatol* 2012; 30: 838–842.
82. Dalakas MC, Sonies B, Dambrosia J, *et al.* Treatment of inclusion-body myositis with IVIg: a double-blind, placebo-controlled study. *Neurology* 1997; 48: 712–716.
83. Walter MC, Lochmuller H, Toepfer M, *et al.* High-dose immunoglobulin therapy in sporadic inclusion body myositis: a double-blind, placebo-controlled study. *J Neurol* 2000; 247: 22–28.
84. Cherin P, Delain JC, de Jaeger C, *et al.* Subcutaneous immunoglobulin use in inclusion body myositis: a review of 6 cases. *Case Rep Neurol* 2015; 7: 227–232.
85. Dastmalchi M, Grundtman C, Alexanderson H, *et al.* A high incidence of disease flares in an open pilot study of infliximab in patients with refractory inflammatory myopathies. *Ann Rheum Dis* 2008; 67: 1670–1677.
86. Barohn RJ, Herbelin L, Kissel JT, *et al.* Pilot trial of etanercept in the treatment of inclusion-body myositis. *Neurology* 2006; 66(2 Suppl. 1): S123–S124.
87. Kosmidis ML, Alexopoulos H, Tzioufas AG, *et al.* The effect of anakinra, an IL1 receptor antagonist, in patients with sporadic inclusion body myositis (sIBM): a small pilot study. *J Neurol Sci* 2013; 334: 123–125.
88. Kitazawa M, Trinh DN and LaFerla FM. Inflammation induces Tau pathology in inclusion body myositis model via glycogen synthase kinase-3beta. *Ann Neurol* 2008; 64: 15–24.
89. Dimachkie MM and Barohn RJ. Inclusion body myositis. *Neurol Clin* 2014; 32: 629–646, vii.
90. Benveniste O, Hogrel JY, Anoussamy M, *et al.* Rapamycin vs. placebo for the treatment of inclusion body myositis: improvement of the 6 min walking distance, a functional scale, the FVC and muscle quantitative MRI [abstract]. *Arthritis Rheumatol* 2017; 69(Suppl 10).
91. Mendell JR, Sahenk Z, Al-Zaidy S, *et al.* Follistatin gene therapy for sporadic inclusion body myositis improves functional outcomes. *Mol Ther* 2017; 25: 870–879.
92. Brown IR. Heat shock proteins and protection of the nervous system. *Ann N Y Acad Sci* 2007; 1113: 147–158.
93. Dalakas MC, Rakocevic G, Schmidt J, *et al.* Effect of Alemtuzumab (CAMPATH 1-H) in patients with inclusion-body myositis. *Brain* 2009; 132: 1536–1544.
94. Lach-Trifilieff E, Minetti GC, Sheppard K, *et al.* An antibody blocking activin type II receptors induces strong skeletal muscle hypertrophy and protects from atrophy. *Mol Cell Biol* 2014; 34: 606–618.
95. Amato AA, Sivakumar K, Goyal N, *et al.* Treatment of sporadic inclusion body myositis with bimagrumab. *Neurology* 2014; 83: 2239–2246.
96. Ioannis M, Foivos P and Dimitrios K. A review on the treatment of sporadic inclusion body myositis with bimagrumab and alemtuzumab. *Int J Neurosci* 2019; 129: 297–302.

97. Hogrel JY, Allenbach Y, Canal A, *et al.* Four-year longitudinal study of clinical and functional endpoints in sporadic inclusion body myositis: implications for therapeutic trials. *Neuromuscul Disord* 2014; 24: 604–610.
98. Limaye VS, Lester S, Blumbergs P, *et al.* Anti-CN1A antibodies in South Australian patients with inclusion body myositis. *Muscle Nerve* 2016; 53: 654–655.
99. Rietveld A, van den Hoogen LL, Bizzaro N, *et al.* Autoantibodies to cytosolic 5'-nucleotidase 1A in primary Sjogren's syndrome and systemic lupus erythematosus. *Front Immunol* 2018; 9: 1200.
100. Lilleker JB, Rietveld A, Pye SR, *et al.* Cytosolic 5'-nucleotidase 1A autoantibody profile and clinical characteristics in inclusion body myositis. *Ann Rheum Dis* 2017; 76: 862–868.
101. Goyal NA, Cash TM, Alam U, *et al.* Seropositivity for NT5c1A antibody in sporadic inclusion body myositis predicts more severe motor, bulbar and respiratory involvement. *J Neurol Neurosurg Psychiatry* 2016; 87: 373–378.
102. Tawara N, Yamashita S, Zhang X, *et al.* Pathomechanisms of anti-cytosolic 5'-nucleotidase 1A autoantibodies in sporadic inclusion body myositis. *Ann Neurol* 2017; 81: 512–525.
103. Alexanderson H and Lundberg IE. The role of exercise in the rehabilitation of idiopathic inflammatory myopathies. *Curr Opin Rheumatol* 2005; 17: 164–171.
104. Alexanderson H and Lundberg IE. Exercise as a therapeutic modality in patients with idiopathic inflammatory myopathies. *Curr Opin Rheumatol* 2012; 24: 201–207.
105. Johnson LG, Collier KE, Edwards DJ, *et al.* Improvement in aerobic capacity after an exercise program in sporadic inclusion body myositis. *J Clin Neuromuscul Dis* 2009; 10: 178–184.
106. Wallace A, Pietrusz A, Dewar E, *et al.* Community exercise is feasible for neuromuscular diseases and can improve aerobic capacity. *Neurology* 2019; 92: e1773–e1785.

Visit SAGE journals online
[journals.sagepub.com/
home/tab](https://journals.sagepub.com/home/tab)

 SAGE journals